

# The Effect of Guided Imagery in Reducing Pain Intensity in Costa Fracture Patients with Levine Theory Approach: A Case Study

<sup>1</sup>Anna Tri Wahyuni

<sup>1</sup>Rumah Sakit Umum Daerah Dr.Kanujoso Djatiwibowo, Balikpapan  
Correspondensi: [annazahra30@gmail.com](mailto:annazahra30@gmail.com)

Received : 30-03-2024

Revised : 20-06-2024

Accepted : 01-10-2024

**Abstract:** Background: Pain in fracture patients is one of the symptoms of a partial or total bone tissue discontinuity damage that causes discomfort. One of the nonpharmacological therapies used according to evidence-based nursing is guided imagery. People with health problems ranging from musculoskeletal problems to terminal illnesses have used guided imagery to relieve symptoms, find meaning, stimulate healing, and make changes, stimulate healing, and make important lifestyle changes that support and encourage healing. However, the use of this implementation is still minimal in nursing. Therefore, this research study was conducted to assess the effect of guided imagery in reducing pain intensity, especially in fracture patients. Method: The method of writing this article uses case studies in patients with costa fractures. Results and Discussion: After 3 days of guided imagery with Levine's theoretical approach, pain decreased from a scale of 6/10 to 3/10. Conclusions: Guided imagery is effective in reducing pain with Levine's theory approach in costa fracture patients.

**Keywords :** Fracture, Guided Imagery, Reduce Pain

## BACKGROUND

The bone fragment shifting or breaking of bone continuity caused by trauma either directly, indirectly, or through pathological conditions is called a fracture (broken bone). Disruption of the discontinuity causes the surrounding soft tissue that supports radiological examination to show bone injury but cannot show muscle or ligament tears, severed nerves, or ruptured blood vessels, so it can cause complications if not treated immediately (1). Thoracic trauma occurs in almost 50% of all accidents, and the most common presentation is rib fractures or rib fractures (2). Based on the Western Trauma Association (WTA), around 10% of deaths in young adults are caused by rib fracture injuries involving the head, abdomen, and extremities, while cases of fractures caused by chest trauma in Indonesia reach a prevalence of 2.6% (3). The effect of torn ligaments causes severed nerves that stimulate sensory nerves through nociceptive neurophysiological processes to the cerebral cortex, which interprets discomfort as pain. Pain is a multidimensional sensory experience with different intensity phenomena (mild, moderate, severe), quality (dull, burning, sharp), period (transient, intermittent, persistent), and spread (superficial or deep, localized or diffuse) (3). Pain causes social isolation and depression. Postoperative fracture clients often feel severe pain, especially when moving (4). This causes patients to experience immobility so that fracture wounds will take a long time to heal and have an impact on prolonged hospitalization. Although analgesic therapy can reduce pain, continuous use can have side effects and affect the economy.

In a study by Pellino and colleagues, it was found that the use of non-pharmacological postoperative therapy resulted in less opioid use on the first and second postoperative days, and patients showed a tendency to reduce anxiety; this has a positive effect on facilitating the recovery process (2). Imagery is a non-pharmacological intervention that can be accessed in a variety of ways at a low cost.

Various methods incorporate imagery, but regardless of the form or name, the technique usually involves a psychological representation of a future situation, task, or event, one of which is guided imagery (5). Guided imagery is guided meditation/imagination, visualization, mental rehearsal, or guided self-hypnosis that lasts a few moments. Guided imagery is based on the idea that the mind and body are interconnected and can interact bilaterally. The brain is stimulated to imagine an event positively and affirmatively before experiencing the actual event. In essence, the individual is guided to develop a mentally beneficial image by focusing on the imagination to feel, see, hear, and smell the event as if it were real. The effects of guided imagery are relaxation, stress reduction, anxiety reduction, improved immune system, and overall well-being (5).

Mira E. Levine is one of the leading experts in nursing conservation theory that focuses on energy conservation, structural integrity, personal integrity, and social integrity, which focuses on improving the client's ability to adapt as quickly as possible to achieve optimal quality of life. The main focus of Levine's model is adaptation, wholeness, and conservation (6). The goal of conservation is to optimize health and strength to face disability. Adapting to the body's internal and external environment is needed to overcome discomfort disorders due to pain to accelerate recovery (6). The purpose of this case study is to identify the effect of guided imagery in reducing pain intensity, especially in patients with rib fractures with Levine's theoretical approach to improve the client's ability to cope with pain and accelerate the recovery process.

## METHODS

This research is a case study, a form of qualitative research based on human understanding and behavior based on thinking. In its discussion, a researcher must be more careful, thorough, and in-depth in finding a case, an individual or group event (7). The sample of this study was a patient with pneumothorax fracture of the 8-9 left rib and close fracture of the ulna dextra et sinistra at the Balikpapan City Regional General Hospital, one of the cities in East Kalimantan Province. Data was collected using interview methods, observation, and review of patient medical records.

## RESULT AND DISCUSSION

An. R, 16 years old, came to the emergency room in a somnolent state GCS: E3M5V4 post-traffic accident between a motorcycle and a car. There were injuries to the left chest, abrasions on the knee, and a tear on the forehead; both wrists appeared deformed. A primary survey was performed; the airway was clear, there were no cervical fractures, normal light reflexes, or isochorous pupils, and no lateralization was found. Blood pressure 127/70 mmHg, Pulse 121x/minute, Respiration 28x/minute, Temperature: 36.0 C, Lung sounds: right vesicular/left not audible—pain Scale NRS (Numeric Rating Scale): 6, no nostrils. The client was planned for WSD installation. A urinary catheter was installed, producing 2cc/kgBW/hour.

When the assessment was conducted, the client was in the room with WSD installed with a one-bottle system on the left chest. This aims to allow air and fluid drainage from the pleural space to flow into the bottle but does not allow air to return to the chest. The client is in a state of Compositis; there are injuries to the left chest, a laceration on the forehead has been heated, abrasions on both feet, and both hands are spalled. The right lung sound is vesicular, while the left is still weak, with vital signs within normal limits. Laboratory results showed Hb: 14.7 g / dl, leukocytes 14.3 thousand, erythrocytes 5.1, Ht 42.7%, platelets 241 thousand, and GDS 113 mg/dl. The Lymphocyte value showed a low value of 6.4%, while Neutrophils showed a high value of 87.1%. This is because the client, after installing the WSD post-trauma chest, is at risk of infection, so the neutrophil value is high. The main complaint felt by the client is pain in

the left chest and the area around the installation of WSD, especially when breathing; both hands also hurt when moved. The client is on bed rest with a semi-fowler position of 30°; the position of both hands is displayed, and the client's spleen can tilt right and left independently. The client is attached to a 3 lpm nasal cannula of oxygen and a 20 tpm RL infusion. The chest wall movement is symmetrical and undulated in the WSD tube. There is a significant difference in the client's x-ray results before and after WSD installation. The results of the chest x-ray interpretation are fractures of ribs 8-9 with left pneumothorax.

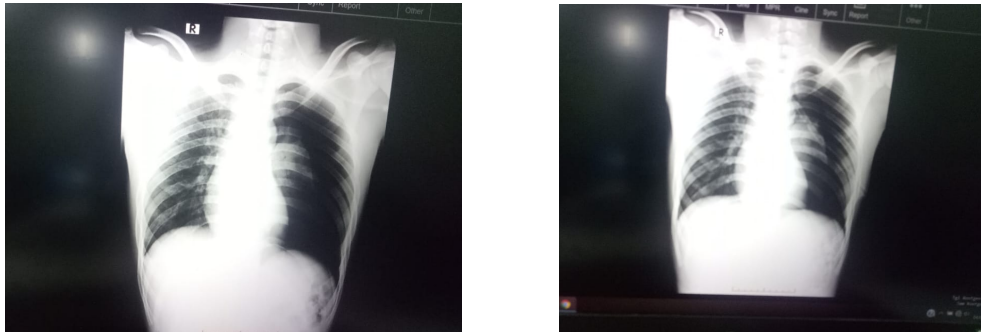


Figure 1 & 2 : Rontgen thorax Pre and Post WSD

Based on the image above, air enters the space between the lungs and the pleural layer covering the left lung. However, after the WSD was installed, air decreased in the left lung. In this case study, the researcher used Levine's energy conservation theory. In Levine's central concept, namely adaptation, there are three main characteristics, namely historicity as a patient's process in maintaining their integrity in environmental reality, specificity of individual response patterns that are uniquely designed to ensure success in essential life activities, and redundancy which is a system or pathway if it cannot ensure adaptation, then other pathways may be able to take over (6). In this case, the nurse must be able to identify the patient's complaints to determine the nursing care provided.

Based on the North American Nursing Diagnosis Association (NANDA), the nursing diagnosis in this case is acute pain related to physical injury agents. One of the nursing interventions given is pain management, namely, carrying out pain management and non-pharmacological guided imagery therapy. The nurse will teach imagery techniques and evaluate the results of the method. From several studies conducted, the effect of non-pharmacological therapy with guided imagery can reduce the intensity and scale of pain in fracture patients. It is known that the benefits of non-pharmacological guided imagery therapy can help improve monitoring, reduce depression, reduce stress and anxiety, reduce pain, reduce side effects, improve sleep patterns, improve quality of life, increase relaxation, reduce nausea, lower blood pressure, promote healing, strengthen the immune system, to reduce respiratory disorders, and reduce severity and increase self-confidence (4). This can occur due to stimulation of client autonomy, which physiologically helps the healing process. By the concept of Levine's Conservation theory, the formulation of statements or justification of problems is called Trophicognosis. Trophicognosis is designated according to the problems and needs of clients who require treatment based on clinical manifestations found in clients (8). Trophicognosis is pain, so the researcher can make a hypothesis. Nursing hypotheses based on previously determined problem formulations, researchers make hypotheses and seek validation together with patients (8). The hypotheses made by researchers are:

1. Carrying out therapeutic communication techniques to find out the patient's pain experience.
2. Evaluating past pain experiences.
3. Controlling the environment that can affect pain, such as room temperature, lighting, and noise.
4. Teach guided imagery techniques to reduce pain precipitation.
5. The effectiveness of pain control is evaluated.

Imagery is a natural way for the human nervous system to store, access, and process information as a coding system where memories, fantasies, dreams, daydreams, and hopes are stored. The body is physiologically inclined to respond to these images as real experiences. In various studies, guided imagery affects almost every physiological control system in the body, including respiration, heart rate, blood pressure, metabolic rate in cells, gastrointestinal motility and secretion, sexual function, and even the body's immune response (9). The release of endorphins (morphine-like substances produced by the body that inhibit the transmission of pain impulses) causes a pleasurable stimulus (4). The exact mechanism of guided imagery is not known for sure. Still, there is research suggesting the possibility through the gate control theory that "only one impulse can travel down the spinal cord to the brain at a time" and "if this pathway is occupied by other thoughts, then the sensation of pain cannot be sent to the brain, and therefore the pain is reduced" (4). The mechanism by which guided imagery can stimulate the limbic system in the brain is explained in the pathway in Figure 1 below.

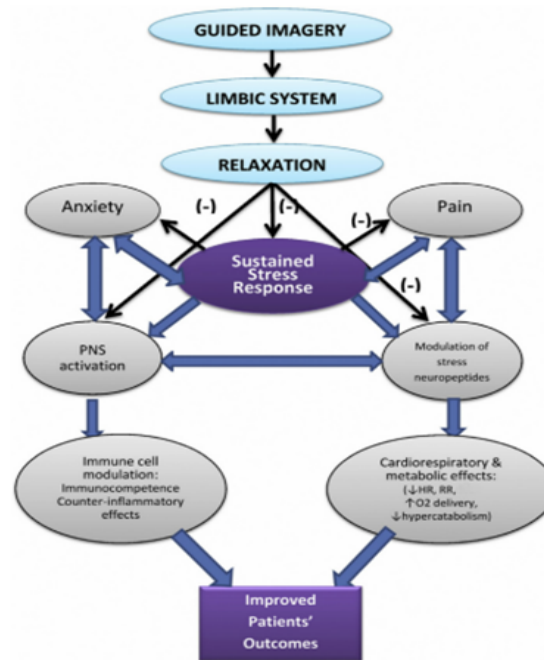


Figure 3 : Guided imagery synthesis mechanism

Inpatient, An.R, aged 16 years, the pain scale using the Numeric Rating Scale (NRS) on a scale of 0-10 was at a pain scale of 6 (moderate category). In addition to receiving analgesic therapy since day 1, the patient was also taught guided imagery techniques with pleasant imagery, namely imagining calm and lovely places (4). The method used was also using soothing classical music using the researcher's cellphone and earphones. This nursing was implemented for 3 days of care from the first day after surgery for 10-15 minutes each day. The researcher tried to explore pleasant things and places that the patient wanted to visit. This aims to divert the pain felt and motivate the patient to practice early mobilization. Based on the intervention results, the pain scale felt by patient An.R gradually decreased from a pain scale of 6 to a pain scale of 3 (mild category) on the third day.

Classical music therapy in post-fracture surgery patients is appropriate for relaxation, especially in reducing pain intensity. Relaxation techniques minimize muscle relaxation, especially respiratory muscles, and this reduces pain (10). Guided imagery stimulates the central control process and is influenced by past experiences. In pain management, reviewing and exploring past pain experiences and patient efforts to overcome pain are interventions that are carried out. In the study conducted, the results obtained were that pediatric patients treated for post-orthopedic surgery had significantly lower subjective anxiety and pain and lower systolic blood pressure after receiving relaxation intervention with guided imagery compared to the control group (12).

## DISCUSSION

Based on the research conducted for 3 consecutive days, on the third day, there were no changes in abnormal vital signs, including Blood Pressure 120/80 mmHg, Pulse 84x/minute, Spontaneous Breathing 20x/minute, Temperature 36.0 C with a pain scale of 3. The plan to remove the WSD is also scheduled for 2 more days if there are no significant complaints. The sound of the left lung is vesicular and more clearly audible. The ORIF plan for ulna fractures will be scheduled after returning home from the hospital. The patient also felt more relaxed in dealing with pain. After the guided imagery technique, the patient also conveyed feelings of calm and happiness. Hopefully, this therapy will be helpful when the patient feels pain at home without using analgesics. Providing analgesics and guided imagery has been shown to provide greater comfort than just giving analgesics to patients with fractures (10). In a study conducted by Ayu (2017) based on the level of post-fracture surgery pain after treatment in the intervention group, the results obtained from 14 respondents after being given audio-recorded guided imagery therapy with deep breathing, the level of pain that was previously at a moderate level decreased to mild pain (77.8%). Audio-recorded guided imagery is a non-pharmacological therapy that is an independent nursing intervention combined with deep breathing relaxation techniques to reduce client pain after fracture surgery. With the help of audio or sound, it is hoped that clients can feel more relaxed and stimulate the client's brain and emotions to imagine more deeply.

The study conducted (11) describes the "M" touch technique combined with guided imagery, showing the most significant prediction of reducing pain and anxiety compared to regular care. The 'M' touch technique is a structured touch method created by Jane Buckle, PhD, which is described as a series of gentle, slow, stroking movements performed in a specific sequence that causes the person being touched (the recipient) to experience greater relaxation and reduced anxiety. The "M" technique differs from other massage techniques in that it uses structured touch, focusing on two of the most sensitive and connected areas of the body, the hands and feet, performed in a set pattern, sequence, and speed that never changes while involving the recipient in determining a consistent level of pressure. Van Kuiken describes four types of guided imagery, which include pleasant imagery (imagining a calm and pleasant

place), physiologically focused imagery (focusing on the physiological functions of the area that is painful and in need of healing), mental rehearsal or reframing (imagining) the event before it occurs, and receptive imagery (scanning the body by imagining immediate healing) (12). Studies have shown that guided imagery therapy affects pain more quickly than prescribed analgesics. The effects of this therapy can reduce pain and help speed up the client's overall recovery. Side effects from the use of analgesics can also be reduced because of the influence of guided imagery therapy on patients with post-operative fractures, so it is possible to reduce the use of analgesics (13). Guided imagery can be very compelling in children because they tend to be more suggestive than adults and more open to their own creativity and imagination (14). Levine's theoretical model describes the complex way that allows a person (child) to adapt despite difficult obstacles. The conservation model is considered appropriate for children because it has 4 (four) assessments of Levine's conservation principles, namely energy conservation, structural integrity conservation, personal integrity conservation, and social integrity conservation, to assess whether the child can carry out the adaptation process. In this way, it is hoped that children can face obstacles, adapt and maintain their uniqueness. The role of nurses in providing nursing care is vital. Specialist nurses must be able to assess and manage care for pre-intra and post-operative patients. Nurses with more knowledge and analytical thinking skills must be involved in collaboration and direct management of patient care to ensure better clinical outcomes (15). Therefore, in this case, Levine's theory is appropriate for pediatric patients. Levine's conservation model began the development of a medical-surgical nursing framework based on nursing therapeutic interventions with the aim of conservation functions. Nurses can also implement supportive patient care plans or therapy to help patients achieve integrity. This is by the principle of treating fracture patients by providing actions that can solve the patient's problems (16).

## CONCLUSION

Based on the analysis, guided imagery can reduce pain in patients with rib fractures using the Levine theory approach. On the third day, patient An. R's pain scale decreased from 6/10 to 3/10. This shows that this therapy can accelerate the patient's recovery process and shorten the Length of Stay in the Hospital. This technique can also be applied to other postoperative patients so that patients can immediately return to their activities and reduce the incidence of infection in the Hospital.

## ACKNOWLEDGEMENTS

Thank you to the Director of Dr. Kanujoso Djatiwibowo Balikpapan Hospital and the case study supervisor and all staff who have helped this research both directly and indirectly, especially to the Head of Nursing who has supported the researcher in this research.

## REFERENCES

1. Black JM, Hawks JH. Keperawatan Medikal Bedah: Manajemen Klinis Untuk Hasil Yang Diharapkan. Buku 3. Edisi Ke-8. Suslia A, Ganiajri F, Lestari PP, Sari RWA, editors. Singapura: Elsevier; 2014.
2. Kim M, Moore JE. Chest Trauma: Current Recommendations for Rib Fractures, Pneumothorax, and Other Injuries. *Curr Anesthesiol Rep*. 2020;10(1):61–8.
3. Bahrudin M. Patofisiologi Nyeri (Pain). *Saintika Med*. 2018;13(1):7.
4. Ayu NMS. Efektifitas Terapi Audio Recorded Guided Imagery Dengan Nafas Dalam Terhadap Penurunan Nyeri Pasien Pasca Operasi Fraktur. *J Keperawatan*. 2017;7(2):725–39.
5. Krau SD. The Multiple Uses of Guided Imagery. *Nurs Clin North Am*. 2020;55(4):467–74.

6. McClelland HM. Nursing theory: utilization & application (2nd edition). Vol. 10, Accident and Emergency Nursing. 2002. 113 p.
7. Hidayat Taufik. Pembahasan Studi Kasus Sebagai Bagian Metodologi Pendidikan. J Study Kasus. 2019;(August):128.
8. Hartini S. Aplikasi model konservasi myra e levie dalam asuhan keperawatan pada anak dengan demam di ruang rawat infeksi anak RSUPN Dr. Cipto Mangunkusumo Jakarta 2012. 2012. 63–85 p.
9. Rossman ML. Guided Imagery and Interactive Guided Imagery. M L Guid Imag Self Heal an Essent anyone Seek wellness. 2000;930.
10. Negara CK, Murjani A, Martiana A, Kurniawan F. Guided Imagery Using Classical Music On The Reduction In Pain Level Of Fracture Patients Institute Of Health Science Cahaya Bangsa Banajrmasin. Injec. 2019;4(1):43–7.
11. Forward JB, Greuter NE, Crisall SJ, Lester HF. Effect of Structured Touch and Guided Imagery for Pain and Anxiety in Elective Joint Replacement Patients--A Randomized Controlled Trial: M-TIJRP. Perm J. 2015;19(4):18–28.
12. Hart J. Guided imagery. Altern Complement Ther. 2008;14(6):295–9.
13. Astuti ND, Respati CA. Pengaruh Terapi Guided Imagery Terhadap Nyeri Pada Pasien Post Operasi Fraktur Di Ruang Bougenvil RSUD Dr. R. Koesma Tuban. J Midpro. 2018;10(2):52.
14. Felix MM dos S, Ferreira MBG, da Cruz LF, Barbosa MH. Relaxation Therapy with Guided Imagery for Postoperative Pain Management: An Integrative Review. Pain Manag Nurs. 2019;20(1):3–9.
15. Masfuri M, Waluyo A, Afyanti Y, Hamid AYS. Educational background and clinical nursing tasks performed by nurses in Indonesian hospitals &. Enfermería Clínica. 2019;29:418–23.
16. Laksmi IAA, Kristianto H, Suharsono T. Application of Levine's Model in Nursing Care of Patient with Diabetic Foot: A Case Study. J A Sustain Glob South. 2020;4(1):6.
17. Riset Kesehatan Dasar (Riskesdas). (2018). Jakarta: Badan Penelitian dan Pengembangan Kesehatan Kementerian RI tahun 2018.